

STRUCTURAL CHANGES IN THE WALL OF THE SMALL INTESTINE OF RATS UNDER THE CONDITIONS OF ACTION OF NIKOLSKY'S VIPER (*VIPERA BERUS NIKOLSKII*) POISON

O. Maievskiy¹, O. Mudrak², A. Parfenyuk³, Ye. Tkach³, O. Tertychna³

¹Київський національний університет ім. Тараса Шевченка (м. Київ, Україна)
e-mail: maievskiyalex8@gmail.com; ORCID: 0000-0002-9128-1033

²КЗВО «Вінницька академія безперервної освіти» (м. Вінниця, Україна)
e-mail: ov_mudrak@ukr.net; ORCID: 0000-0002-1776-6120

³Інститут агроекології і природокористування НААН (м. Київ, Україна)
e-mail: vereskrpar@ukr.net; ORCID: 0000-0003-0169-4262
e-mail: bio_eco@ukr.net; ORCID: 0000-0002-0666-1956
e-mail: olyater@ukr.net; ORCID: 0000-0002-9514-2858

*Компоненти отруту різних живих видів викликають в організмі жертви широкий спектр ефектів і симптомів. Механізми ураження різних органів і систем тварин та людини під впливом специфічних компонентів токсинів отрути гадюк залишаються відкритими. Тому дослідження механізмів дії отрути гадюки, а також розробка і впровадження комплексу заходів щодо зменшення негативного впливу їх отрути на організм ссавців залишаються актуальними. Вивчення еколого-біологічних аспектів порушення гомеостазу організму щура в умовах дії отрути гадюки є складним і багатограним процесом, який охоплює різні наукові напрями. Мета дослідження — виявити ознаки ураження тонкої кишки щурів за умов дії отрути гадюки нікольського (*Vipera berus nikolskii*). Експеримент проводився на 20 білих щурах-самцях. У дослідженні щурів розділили на дві групи — контрольну і дослідну. Отруєння моделювали введенням отрути гадюки нікольського щурам дослідної групи внутрішньочеревно в дозі ЕД₅₀ 0,972 мг/г. Гістологічні препарати досліджували на світловому мікроскопі SEO SCAN, обробку знімків проводили за допомогою камери Vision CCD з наявною системою виведення зображень на монітор комп'ютера. Встановлено, що важка інтоксикація організму отрутою гадюки нікольського щурам дослідної групи обширні деструктивно-дистрофічні зміни в стінці порожнього кишківника, поряд зі значними стромально-судинними порушеннями. Отруйні гемотоксини підвищують проникність судинної стінки та змінюють процеси внутрішньосудинного згортання крові, що призводить до дисемінованого внутрішньосудинного згортання крові (синдром ДВС) і незворотної дегенерації структур тонкої кишки в експерименті.*

Ключові слова: гадюки, тонкий кишечник, токсини, структурні зміни, отрута.

INTRODUCTION

The components of the poisons of various living species cause a wide range of effects and symptoms in the victim's body. In this case, the severity of pathological changes is determined mainly by the type of poisonous animal, the total amount of the toxin, the method of its introduction and the characteristics of the recipient. Among the variety of toxic animals, vipers have attracted the most excellent attention of scientists for several

centuries. To date, the composition of viper venom has been studied quite well. However, the mechanisms of damage to various organs and systems of animals and humans under the influence of specific components of their toxins remain open. This understanding is critical to effectively managing poisoning, a severe problem. On the other hand, these toxins' high selectivity and efficiency make them valuable tools for basic research. In addition, toxins with known mechanisms of action can be a source for drug development.

All this indicates that studying the mechanisms of action of viper venom and its toxins is very complex and vitally important [1; 2]. Therefore, the study of the mechanisms of action of the viper venom *Vipera b. nikolskii*, as well as the development and implementation of a set of measures to reduce the negative impact of their poison on the body of mammals, remain relevant. The study of the ecological and biological aspects of the violation of the homeostasis of the rat organism under the conditions of the action of the viper venom *Vipera berus nikolskii* (the most common in Ukraine) is a complex and multifaceted process that affects various scientific directions – ecology, biology, toxicology, pharmacology, pathophysiology, pathomorphology. This requires using different scientific research methods (ecological, biochemical, morphological, etc.).

The purpose of the study is to identify signs of damage to the small intestine of rats under the conditions of the poison of Nikol'sky's viper (*Vipera berus nikolskii*).

ANALYSIS OF RECENT RESEARCH

Among the bulk of the components of the viper poison, the most significant proportion belongs to various enzymes. Of all enzymes, phospholipase A2 accounts for about 65% of dry weight, and serine proteases – 19%. The venom of vipers contains two heterodimeric phospholipases A2. They differ in the kinetics of catalytic hydrolysis. The mechanism of the toxic action of these heterodimers has not yet been clarified [3–6]. However, phospholipase A2 comprises a catalytically active subunit β and an inactive subunit α . The enzyme's activity on the bilipid layer of the cell membrane causes its aggregation. The components of viper venom have a predominantly hemotoxic effect due to a wide variety of enzymes from the family of metalloproteinases, serine proteases, L-amino acid oxidases and lectin-like C-type proteins, leading to increased blood clotting. L-amino acid oxidases block neuromuscular impulse transmission and destroy cell membranes. The venom also contains several proteins that have a neurotoxic ef-

fect. Among them are CRP (cysteine-rich proteins) which blocks the transmission of nerve impulses, and phospholipase A2, which has neuro-, myo-, cyto- and hemotoxic effects. Hemotoxins, in this case, are classified into factors that activate blood clotting, anticoagulants, inhibitors, and platelet activators, agents that cause fibrinolysis. Proteins of the first group affect blood coagulation factors. Anticoagulant hemotoxins include serine proteases, phospholipase A2, and activators of protein C. Platelet-activating proteins are predominantly lectin-like in nature [7–13]. Disintegrins and metalloproteinases represent platelet deactivators. There is also a group of so-called haemorrhaging – cytolysins, which damage the wall of blood vessels and cause haemorrhages [14–17].

MATERIALS AND METHODS OF RESEARCH

The experiment was conducted by international recommendations for conducting biomedical studies on animals [18]. These guidelines included the «General Principles for the Treatment of Animals», adopted by the 1st National Congress on Bioethics in Kyiv, Ukraine, in 2001, and the «European Convention for the Protection of Vertebrate Animals Used for Experimental and Other Scientific Purposes» in Strasbourg, France in 1986. The Committee on Bioethics of the Research Center «Institute of Biology and Medicine» of Taras Shevchenko National University of Kyiv certified the compliance of the experiment with ethical principles (protocol No. 2 was approved on August 19, 2021). During the investigation, the rats were kept separately in the vivarium conditions and received a standard diet. Before taking the test substances, the rats were acclimatised in the experimental room for at least five days. The rats in the study were divided into two groups. The first group received intraperitoneal saline 0.5 ml. The second group was administered venom of Nikol'sky's viper at a dose of ED₅₀ of 0.972 $\mu\text{g/g}$ by intra-abdominal injection. Crude lyophilised poison of *V. berus nikolskii* was obtained from V.N. Karazin Kharkiv National University, stored at

a temperature of -20°C and immediately dissolved in saline before the experiment. The solution was centrifuged at 10,000 g for 15 minutes, and the supernatant was used in the study. A day later, the rats were removed from the experiment by overdosing on sodium thio-pental and decapitation. All animals of both groups were weighed before. Subsequently, the animals were dissected, and macroscopic examination and description of all internal organs were performed. The identified pathological changes were recorded and examined morphologically. For microscopic analysis, fragments of the small intestine were taken. The pieces were fixed in a 10% formalin solution; the ageing time did not exceed 1–2 days. To prevent autolysis and prepare cells and tissues for staining, a fixing solution was applied, which stabilised them. After that, the fragments were dehydrated in increasing concentrations of alcohol and then poured into paraffin blocks. The resulting sections were 4–5 microns thick and stained with hematoxylin and eosin. Histological preparations were examined using an SEO SCAN light microscope, and the images were processed with a Vision CCD camera. The processed

images were displayed on a computer monitor [19].

RESULTS AND DISCUSSION

Microscopic studies of the empty bowel wall of experimental animals when bitten by Nikolsky's viper (*Vipera berus nikolskii*) established a more significant degree of damage to structural components and organ relief, pathological changes in the stroma and vascular bed, compared to the previous experimental group. The organ retains its layered structure but with significant destructive-degenerative changes in relief, pronounced stromal-vascular disorders of the empty bowel wall, and significant swelling of the mucous membrane, which is covered with serous-mucous secretion (Fig. 1).

In areas of the mucous membrane with its typical relief preserved, villi are observed in the epithelium where hyperplastic goblet cells increase significantly and dystrophy of enterocytes with a striped border. Significant destructive changes exist in the basement membrane of the epithelial plate of villi. In the stroma of villi with complete desquamation of the epithelium on their distal surface, pronounced oedema. Increased vascular tissue permeability of the stroma of villi leads to pronounced hydration of the amorphous substance of loose fibrous connective tissue. Collagen fibres, in areas with severe oedema, are pronounced acidophilus. Fibres retain their bundle nature. In the area of oedema, there are a small number of fibroblastic cells, histiocyte macrophages, and lymphocytes.

There are unevenly thickened villi, club-shaped reduced distal sections, shortening of villi with significant deformation, graceful, atrophic villi, villi with the formation on their surface of single erosions and villi, which are soldered together and have the appearance of polyp. On the surface there are destructively altered villi of serous-mucous secretion. In their stroma are many fibroblastic cells and pronounced infiltration by lymphocytes, plasma cells and macrophages-histiocytes (Fig. 2). Collagen fibres are in the form of massive bright eosinophilic bundles.

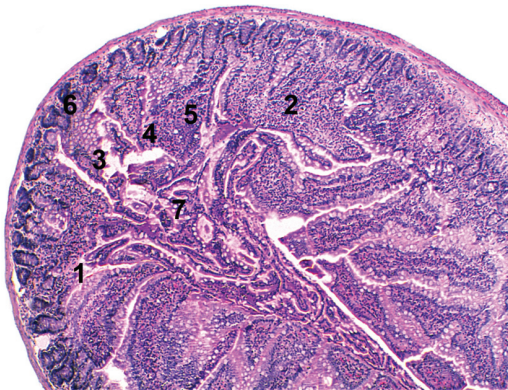


Fig. 1. Microscopic changes in the wall of the empty intestine of white rats with the bite of Nikolsky's viper: 1 – villous atrophy, 2 – villi in the form of polypoid outgrowths, 3 – desquamation of the villi epithelium, 4 – villi with desquamative-erosive phenomena, 5 – acute necrotic villi lesions, 6 – deformed crypts, 7 – desquam epithelial detritus in the intestinal lumen. Hematoxylin-eosin staining. $\times 100$

There are also single mucous membrane areas with atrophy of the crypts, villi and areas with acute necrotic villi lesions. Atrophy of single villi develops due to a significant decrease and slowdown in blood flow in hemocapillaries (stasis and blood clots). Tissue hypoxia leads to a substantial reduction in cell size and to the necessary stimulation of fibroblast proliferation. In foci of acute necrosis, exocryocytes lose their striped rim; goblet cells are significantly hyperplasia. The cytoplasm of all cells is acidophilic; their nuclei increase considerably in volume, weakly basophilic with a gradual erosion of their contours (undergo lysis) and significant destructive changes in the basement membrane. The villous stroma, which borders on foci of epithelium necrosis, also undergoes necrotic changes. Bundles of collagen fibres are maximally compacted and appear as a homogeneous mass in the centre of weakly basophilic and oxyphilic along the periphery. Demarcation inflammation occurs around the foci of necrosis – significant infiltration by leukocytes and macrophages. Along the periphery of the zone of necrotic changes in the intercellular substance of connective tissue, the number of cells of the fibroblastic series increases significantly. In these zones, the hemocapillaries are sharply dilated and full-blooded, with significant hydration of the stroma along their periphery and many leukocytes and macrophages. In crypts, the number of cells at different stages of mitosis is significantly reduced, and crypts are deformed and atrophied. There are areas of mucous membranes with a complete absence of crypts (*Fig. 3*).

The vessels of the mucous membrane of the organ are sharply dilated and blood-filling. The vascular wall is thickened with severe perivascular oedema and significant lymphohistiocytic infiltration, and an increase in the number of tissue basophils. The structure of the wall of hemocapillaries of destructively altered villi is blurred; their lumen is sharply expanded and blood-filled. The endothelium of the hemocapillary wall loses its flattened shape. The basement membrane of hemocapillaries is as elegant as possible, not continuous.

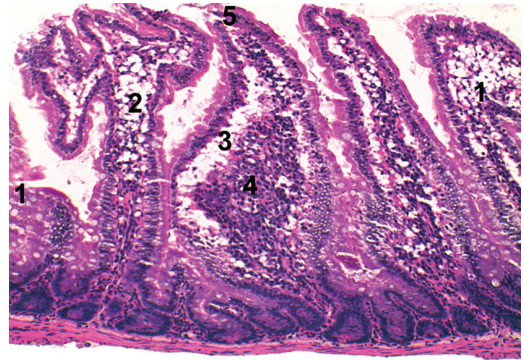


Fig. 2. The microscopic structure of the wall of the empty intestine of white rats with the bite of Nikolsky's viper: 1 – deformed villi, 2 – villi in the form of a polypoid outgrowth, 3 – villi stromal oedema, 4 – histolleukocyte villous stromal infiltration, 5 – villi with desquamative-erosive phenomena. Hematoxylin-eosin staining. $\times 200$

In their lumens, there are stasis and numerous blood clots. Blood clots contain blood cells and plasma proteins, which form a structureless homogeneous eosinophilic mass. Violation of blood coagulation processes and violation of the integrity of the walls of the blood

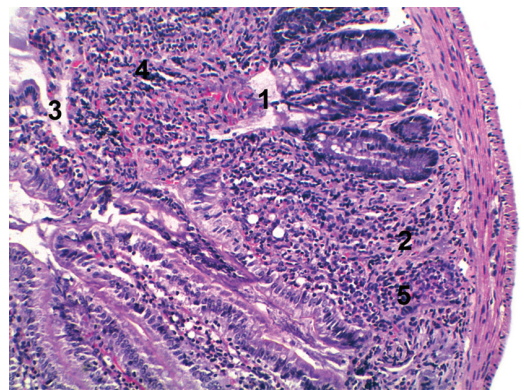


Fig. 3. Microscopic changes in the wall of the empty intestine of white rats with the bite of Nikolsky's viper: 1 – villous atrophy, 2 – crypt atrophy, 3 – desquamation of the villi epithelium, 4 – histolleukocyte villous stromal infiltration, 5 – mucous membrane area with the complete absence of crypts. Hematoxylin-eosin staining. $\times 200$

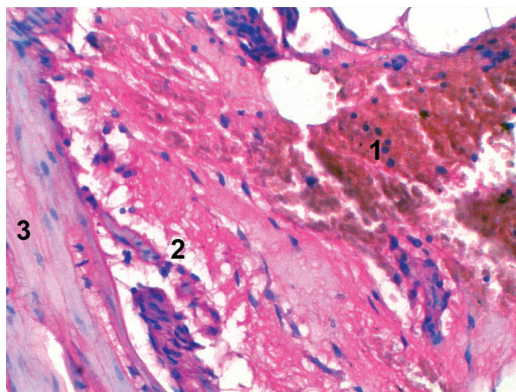


Fig. 4. Microscopic changes in the wall of the empty intestine of white rats with the bite of Nikolsky's viper: 1 – massive haemorrhage in the mucous membrane, 2 – swelling of the stromal connective tissue, 3 – muscular membrane. Hematoxylin-eosin staining. $\times 400$

capillaries of the own plate of the mucous membrane leads to the appearance of multiple and massive haemorrhages with hemolysis of red blood cells in the stroma villi. Along the periphery of haemorrhages, significant fibroblastic and lymphohistiocytic stromal infiltration is observed (Fig. 4).

In layers of loose fibrous connective tissue, between two layers of smooth muscle

tissue of the muscular membrane, the vessels are with sharply expanded lumens. There is a significant oedema in the vascular wall, massive haemorrhages along the vessels and significant perivascular lymphohistiocytic infiltration. The serous membrane is significantly elegant. The mesothelium is flattened as much as possible; the basement membrane is elegant—bundles of collagen fibres with severe oxyphilia.

CONCLUSIONS

A histological study of the small intestine wall was conducted on experimental animals after exposure to Nikolsky's viper venom. The findings indicated:

1. Severe body intoxication from the venom of *Vipera berus nikolskii* causes extensive destructive and degenerative changes in the wall of the jejunum, along with significant stromal-vascular disorders.

2. The hemotoxins in the venom increase vessel wall permeability and alter intravascular blood coagulation processes, resulting in disseminated intravascular coagulation (DVS-syndrome) and irreversible degeneration of small intestine structures in the experiment.

ЛІТЕРАТУРА

1. Utkin Y. Animal Venoms and Their Components: Molecular Mechanisms of Action. *Toxins* (Basel). 2021. Vol. 13 (6). P. 415. DOI: <https://doi.org/10.3390/toxins13060415>.
2. Ana L. Oliveira, Matilde F. Viegas, Saulo L. da Silva et al. The chemistry of snake venom and its medicinal potential. *Nat Rev Chem*. 2022. Vol. 6 (7). P. 451–469. DOI: <https://doi.org/10.1038/s41570-022-00393-7>.
3. Alekseeva A.S., Tretiakova D.S., Chernikov V.P. et al. Heterodimeric *V. nikolskii* phospholipases A2 induce aggregation of the lipid bilayer. *Toxicon*. 2017. Vol. 133. P. 169–179. DOI: <https://doi.org/10.1016/j.toxicon.2017.05.015>.
4. Amazonas D.R., Portes-Junior J.A., Nishiyama-Jr M.Y. et al. Molecular mechanisms underlying intraspecific variation in snake venom. *J Proteomics*. 2018. Vol. 181. P. 60–72. DOI: <https://doi.org/10.1016/j.jpropt.2018.03.032>.
5. Dyachenko I.A., Murashev A.N., Andreeva T.V. et al. Analysis of nociceptive effects of neurotoxic phospholipase A2 from *Vipera nikolskii* venom in mice. *J Venom Res*. 2013. Vol. 4. P. 1–4.
6. Zinenko O., Tovstukha I. and Korniyenko Y. PLA2 Inhibitor Varespladib as an Alternative to the Anti-venom Treatment for Bites from Nikolsky's Viper *Vipera berus nikolskii*. *Toxins* (Basel). 2020. Vol. 12 (6). P. 356. DOI: <https://doi.org/10.3390/toxins12060356>.
7. Cesar P.H.S., Braga M.A., Trento M.V.C. et al. Snake Venom Disintegrins: An Overview of their Interaction with Integrins. *Curr Drug Targets*. 2019. Vol. 20 (4). P. 465–477. DOI: <https://doi.org/10.2174/13894501196661022154737>.
8. Er O., Eksin H.M., Göcmen B. et al. Investigation of *Vipera Anatolica* Venom Disintegrin via Intracellular Uptake with Radiolabeling Study and Cell-Based Electrochemical Biosensing Assay. *Appl Biochem Biotechnol*. 2019. Vol. 187 (4). P. 1539–1550. DOI: <https://doi.org/10.1007/s12010-018-2872-6>.
9. Hadar G., Kelmer E., Segev G. et al. Protein C activity in dogs envenomed by *Vipera palaestinae*. *Toxicon*. 2014. Vol. 87. P. 38–44. DOI: <https://doi.org/10.1016/j.toxicon.2014.05.010>.
10. Kryukova E.V., Potapenko A.S., Andreeva T.V. et al. Dimeric Disintegrins from the Steppe Viper *V. ursinii* Venom. *Doll Biochem Biophys*. 2019. Vol. 488 (1).

- P. 338–341. DOI: <https://doi.org/10.1134/S1607672919050132>.
11. Chengbo Long, Ming Liu, Huiwen Tian et al. Potential Role of Platelet-Activating C-Type Lectin-Like Proteins in Viper Envenomation Induced Thrombotic Microangiopathy Symptom. *Toxins* (Basel). 2020. Vol. 12 (12). P. 749. DOI: <https://doi.org/10.3390/toxins12120749>.
 12. Teixeira C., Fernandes C.M., Leiguez E. and Chudzinski-Tavassi A.M. Inflammation Induced by Platelet-Activating Viperid Snake Venoms: Perspectives on Thromboinflammation. *Front Immunol*. 2019. Vol. 10. P. 2082. DOI: <https://doi.org/10.3389/fimmu.2019.02082>.
 13. Anwar Ullah, Rehana Masood, Ijaz Ali et al. Thrombin-like enzymes from snake venom: structural characterization and mechanism of action. *Int. J. Biol. Macromol*. 2018. Vol. 114. P. 788–811. DOI: <https://doi.org/10.1016/j.ijbiomac.2018.03.164>.
 14. Czajka U., Wiatrzyk A. and Lutynska A. Mechanism of *Vipera berus* venom activity and the principles of antivenom administration in treatment. *Przegl Epidemiol*. 2013. Vol. 67 (4). P. 641–646.
 15. Zorica Latinović, Adrijana Leonardi, Cho Yeow Koh et al. The Procoagulant Snake Venom Serine Protease Potentially Having a Dual, Blood Coagulation Factor V and X-Activating Activity. *Toxins* (Basel). 2020. Vol. 12 (6). P. 358. DOI: <https://doi.org/10.3390/toxins12060358>.
 16. Zorica Latinović, Adrijana Leonardi, Jernej Šribar et al. Venomics of *Vipera berus* to explain differences in pathology elicited by *Vipera ammodytes ammodytes* envenomation: Therapeutic implications. *J Proteomics*. 2016. Vol. 146. P. 34–47. DOI: <https://doi.org/10.1016/j.jprotp.2016.06.020>.
 17. Spolaore B., Fernandez J., Lomonte B. et al. Enzymatic labelling of snake venom phospholipase A2 toxins. *Toxicon*. 2019. Vol. 170. P. 99–107. DOI: <https://doi.org/10.1016/j.toxicon.2019.09.019>.
 18. Добре́ля Н.В., Бойцова Л.В., Данова І.В. Право́ва база для проведення етичної експертизи доклінічних досліджень лікарських засобів з використанням лабораторних тварин. *Фармакологія та лікарська токсикологія*. 2015. № 2. С. 95–100.
 19. Горальський Л.П., Хомич В.Т., Кононський О.І. Основи гістологічної техніки і морфофункціональні методи досліджень у нормі та при патології: навч. посіб. Житомир: «Полісся», 2005. 288 с.

REFERENCES

1. Utkin, Y. (2021). Animal Venoms and Their Components: Molecular Mechanisms of Action. *Toxins* (Basel), 13 (6), 415. DOI: <https://doi.org/10.3390/toxins13060415> [in English].
2. Ana, L. Oliveira, Matilde, F. Viegas, Saulo, L. da Silva et al. (2022). The chemistry of snake venom and its medicinal potential. *Nat Rev Chem.*, 6 (7), 451–469. DOI: <https://doi.org/10.1038/s41570-022-00393-7> [in English].
3. Alekseeva, A.S., Tretiakova, D.S., Chernikov, V.P. et al. (2017). Heterodimeric *V. nikolskii* phospholipases A2 induce aggregation of the lipid bilayer. *Toxicon*, 133, 169–179. DOI: <https://doi.org/10.1016/j.toxicon.2017.05.015> [in English].
4. Amazonas, D.R., Portes-Junior, J.A., Nishiyama-Jr, M.Y. et al. (2018). Molecular mechanisms underlying intraspecific variation in snake venom. *J Proteomics*, 181, 60–72. DOI: <https://doi.org/10.1016/j.jprotp.2018.03.032> [in English].
5. Dyachenko, I.A., Murashev, A.N., Andreeva, T.V. et al. (2013). Analysis of nociceptive effects of neurotoxic phospholipase A2 from *Vipera nikolskii* venom in mice. *J Venom Res*, 4, 1–4 [in English].
6. Zinenko, O., Tovstukha, I. & Korniyenko, Y. (2020). PLA2 Inhibitor Varespladib as an Alternative to the Antivenom Treatment for Bites from Nikolsky's Viper *Vipera berus nikolskii*. *Toxins* (Basel), 12 (6), 356. DOI: <https://doi.org/10.3390/toxins12060356> [in English].
7. Cesar, P.H.S., Braga, M.A., Trento, M.V.C. et al. (2019). Snake Venom Disintegrins: An Overview of their Interaction with Integrins. *Curr Drug Targets*, 20 (4), 465–477. DOI: <https://doi.org/10.2174/13894501196661022154737> [in English].
8. Er, O., Eksin, H.M., Göcmen, B. et al. (2019). Investigation of *Vipera Anatolica* Venom Disintegrin via Intracellular Uptake with Radiolabeling Study and Cell-Based Electrochemical Biosensing Assay. *Appl Biochem Biotechnol*, 187 (4), 1539–1550. DOI: <https://doi.org/10.1007/s12010-018-2872-6> [in English].
9. Hadar, G., Kelmer, E., Segev, G. et al. (2014). Protein C activity in dogs envenomed by *Vipera palaestinae*. *Toxicon*, 87, 38–44. DOI: <https://doi.org/10.1016/j.toxicon.2014.05.010> [in English].
10. Kryukova, E.V., Potapenko, A.S., Andreeva, T.V. et al. (2019). Dimeric Disintegrins from the Steppe Viper *V. ursinii* Venom. *Doll Biochem Biophys*, 488 (1), 338–341. DOI: <https://doi.org/10.1134/S1607672919050132> [in English].
11. Chengbo, Long, Ming, Liu, Huiwen, Tian et al. (2020). Potential Role of Platelet-Activating C-Type Lectin-Like Proteins in Viper Envenomation Induced Thrombotic Microangiopathy Symptom. *Toxins* (Basel), 12 (12), 749. DOI: <https://doi.org/10.3390/toxins12120749> [in English].
12. Teixeira, C., Fernandes, C.M., Leiguez, E. & Chudzinski-Tavassi, A.M. (2019). Inflammation Induced by Platelet-Activating Viperid Snake Venoms: Perspectives on Thromboinflammation. *Front Immunol*, 10, 2082. DOI: <https://doi.org/10.3389/fimmu.2019.02082> [in English].
13. Anwar, Ullah, Rehana, Masood, Ijaz, Ali et al. (2018). Thrombin-like enzymes from snake venom: structural characterization and mechanism of action. *Int. J. Biol. Macromol.*, 114, 788–811. DOI: <https://doi.org/10.1016/j.ijbiomac.2018.03.164> [in English].
14. Czajka, U., Wiatrzyk, A. & Lutynska, A. (2013). Mechanism of *Vipera berus* venom activity and the

- principles of antivenom administration in treatment. *Przegl Epidemiol*, 67 (4), 641–646 [in English].
15. Zorica, Latinović, Adrijana, Leonardi, Cho, Yeow Koh et al. (2020). The Procoagulant Snake Venom Serine Protease Potentially Having a Dual, Blood Coagulation Factor V and X-Activating Activity. *Toxins (Basel)*, 12 (6), 358. DOI: <https://doi.org/10.3390/toxins12060358> [in English].
 16. Zorica Latinović, Adrijana Leonardi, Jernej Šribar et al. (2016). Venomics of *Vipera berus* to explain differences in pathology elicited by *Vipera ammodytes* ammodytes envenomation: Therapeutic implications. *J Proteomics*, 146, 34–47. DOI: <https://doi.org/10.1016/j.jprot.2016.06.020> [in English].
 17. Spolaore, B., Fernandez, J., Lomonte, B. et al. (2019). Enzymatic labelling of snake venom phospholipase A2 toxins. *Toxicon*, 170, 99–107. DOI: <https://doi.org/10.1016/j.toxicon.2019.09.019> [in English].
 18. Dobrelia, N.V., Boitsova, L.V. & Danova, I.V. (2015). Pravova baza dlia provedennia etychnoi ekspertyzy doklinichnykh doslidzhen likarskykh zasobiv z vykorystanniam laboratornykh tvaryn [Legal basis for ethical examination of preclinical studies of drugs using laboratory animals]. *Farmakolohiia ta likarska toksykolohiia — Pharmacology and Drug Toxicology*, 2, 95–100 [in Ukrainian]
 19. Horalskyi, L.P., Khomych, V.T. & Kononskyi, O.I. (2011). *Osnovy histolohichnoi tekhniki i morfofunktsionalni metody doslidzhen u normi ta pry patolohii* [Fundamentals of histological technique and morpho-functional research methods in normal and pathology]. Zhytomyr: Polissya [in Ukrainian].

Стаття надійшла до редакції журналу 08.06.2023
